



# Childhood in the Past

## An International Journal

ISSN: 1758-5716 (Print) 2040-8528 (Online) Journal homepage: <https://www.tandfonline.com/loi/ycip20>

# Non-adult Fracture Patterns in Late and Post-medieval Flanders, a Comparison of a Churchyard and a Church Assemblage

Katrien Van de Vijver

To cite this article: Katrien Van de Vijver (2019): Non-adult Fracture Patterns in Late and Post-medieval Flanders, a Comparison of a Churchyard and a Church Assemblage, *Childhood in the Past*, DOI: [10.1080/17585716.2019.1638556](https://doi.org/10.1080/17585716.2019.1638556)

To link to this article: <https://doi.org/10.1080/17585716.2019.1638556>



Published online: 15 Jul 2019.



Submit your article to this journal [↗](#)



View Crossmark data [↗](#)



# Non-adult Fracture Patterns in Late and Post-medieval Flanders, a Comparison of a Churchyard and a Church Assemblage

Katrien Van de Vijver<sup>a,b</sup>

<sup>a</sup>Royal Belgian Institute of Natural Sciences, Brussels, Belgium; <sup>b</sup>Center for Archaeological Sciences, University of Leuven, Leuven, Belgium

## ABSTRACT

The study of trauma in non-adults (<18 years) from archaeological assemblages is relatively recent, partly because immature bones present distinct injury patterns, while rapid healing and remodelling can erase macroscopic evidence. However, non-adult trauma provides information about age-related differences in risk, and the lifestyles and social roles of immature individuals. This study recorded possible fractures in 135 non-adults from a churchyard and a church assemblage from medieval and post-medieval Flanders, to evaluate the presence of fractures and analyse type, prevalence, age distribution, and socio-economic differences. Eighteen individuals presented lesions, including typical non-adult injuries. Prevalence was generally low, but some trends emerged. The churchyard had a higher prevalence, and these individuals likely had a lower social background compared to the church, suggesting socio-economic differences. In the churchyard assemblage older non-adults showed an increased prevalence, possibly related to occupational risks since many children and particularly adolescents, worked as servants, labourers, or apprentices.

## KEYWORDS

Fracture; non-adult; medieval; post-medieval; occupation

## Introduction

### *Skeletal trauma in non-adults*

A common definition of trauma is ‘an injury to living tissue caused by a force or mechanism extrinsic to the body’ (Lovell 1997, 139). Studies of trauma in archaeological assemblages usually record fractures and dislocations, which can be observed in skeletal remains (Lovell 1997; Aufderheide and Rodríguez-Martín 1998; Roberts 2000; Ortner 2003; Waldron 2009; Judd and Redfern 2012). Fractures result from direct or indirect trauma, acute or prolonged stress, or pathological conditions, and the type of force will influence the characteristics of the break. The type and where the fracture is located are important to interpret the mechanism and how the injury was sustained (Lovell 1997). While adult trauma is commonly observed and widely studied, trauma in non-adults

**CONTACT** Katrien Van de Vijver  katvdv83@hotmail.com  Royal Belgian Institute of Natural Sciences, Vautierstraat 29, Brussels B-1000, Belgium; Center for Archaeological Sciences, University of Leuven, Leuven, Belgium

© Informa UK Limited, trading as Taylor & Francis Group and the Society for the Study of Childhood in the Past 2019

(defined here as individuals younger than 18 years of age) from archaeological assemblages has only recently received more attention (Glencross and Stuart-Macadam 2000; Verlinden and Lewis 2015; Lewis 2016, 2018; Redfern 2017). This is at least partly because of the formation of distinct types and patterns of fractures in immature bone, and their rapid healing and remodelling (Jones 1994; Glencross and Stuart-Macadam 2000; Ogden 2000; Lewis 2018). The types of injury seen in non-adults often differ from those seen in adults because of the particular properties of immature bones, which are related to their capacity for growth. The cortex (the compact outer layer of bone) is thinner and more porous and bones are more plastic, which means they can withstand a higher amount of force before they break (Jones 1994; Glencross and Stuart-Macadam 2000; Lewis 2018). The periosteum (a membrane that covers the surface of bones outside the joints) is thicker and stronger, but not as firmly attached to the diaphysis (shaft) and it is more easily damaged. It is also more osteogenic, with a higher level of bone production, and injuries can result in extensive periosteal new bone formation (Jones 1994; Ogden 2000; Lewis 2018). Immature bones also comprise different elements and include epiphyses and cartilaginous growth plates (physes) at the ends of bones where growth occurs, and for example around the articular surfaces of vertebral bodies. Therefore, age and the degree to which epiphyses have formed and fused influence potential trauma sites and types of injury (Verlinden and Lewis 2015; Lewis 2018).

Besides the fracture types that are frequently observed in adults, there are several injuries that are considered to be typical for non-adults. Greenstick or incomplete fractures, which are caused by bending forces, are the most common types that are observed in non-adults, but they are rarely recorded in archaeological studies. They can be identified by localised periosteal new bone formation. Buckle fractures occur when the end of a bone is forced into itself because of impaction or compression, resulting in overlapping bone fragments (Glencross and Stuart-Macadam 2000; Lewis 2018). Plastic bowing deformation occurs as a result of the plastic nature of growing bone and opposing vertical forces. If the pressure continues for a longer time, the bone can stay bowed after the force is removed, while a higher amount of force will cause an incomplete or complete break. Bowing deformities can occur without new bone formation and can be confused with metabolic (related to an inadequate intake of nutrients) or congenital (acquired during development) conditions, or post-mortem damage (Borden 1974; Stuart-Macadam, Glencross, and Kricun 1998; Lewis 2018). It often affects one of the paired bones, particularly the ulna (Stuart-Macadam, Glencross, and Kricun 1998, 254). Physeal trauma includes any injury that affects the growth plate. The scheme by Salter and Harris is widely used and includes five types (Salter and Harris 1963). Physeal injuries may affect only the growth plate, they can include part of the metaphysis and/or epiphysis, or completely detach the epiphysis. New bone formation on or around the physeal surface of bones may indicate injuries. However, physeal trauma is usually recognised through an unusual shape or size discrepancy in bones, which is more commonly recorded in adult bones where it may indicate injuries that were sustained during growth. Injury can result in shortening or asymmetric growth through complete or partial premature closure of the growth plate. Displacement of fragments can result in non-union or deformity. Injuries to blood vessels can cause

necrosis (death of cells in living tissue) and bone resorption (Verlinden and Lewis 2015; Lewis 2018). Physal injuries can be caused by compression, tension, twisting, avulsion, or shearing (Glencross and Stuart-Macadam 2000).

Fractures heal faster in non-adults because their bones are still growing, although this depends on the age, location, severity, and malunion, and the presence of other pathological conditions. This rapid healing of fractures, particularly in younger children, means that they can remodel completely (Jones 1994; Glencross and Stuart-Macadam 2000; Ogden 2000). Potential complications include angulation, overlap or rotation of fragments, infection, and damage to blood supply or nerves (Lovell 1997; Roberts 2000). Angulation may disappear completely under 10 years old, but it can persist in severe deformities. Malrotation cannot be corrected. A delay or lack of fusion are uncommon in non-adults (Jones 1994; Glencross and Stuart-Macadam 2000; Ogden 2000). Typical complications for non-adult fractures are growth arrest or joint deformity resulting from premature closure of the growth plate, or overgrowth, which is associated with increased blood flow (Ogden 2000; Lewis 2018).

Fracture patterns also differ between non-adults of different ages. During growth the cortex becomes thicker and more compact, the periosteum becomes thinner and less osteogenic and epiphyses ossify and eventually fuse (Jones 1994; Glencross and Stuart-Macadam 2000; Lewis 2018). Biological development also influences type and prevalence of fractures. Until around 2 years of age, children depend completely on carers and fractures can suggest abuse. From 1 to 2 years old, children become mobile, which increases the risk of accidents. Activities change and become more varied as children grow older, which influences the risk of accidental injury and the types of trauma they may sustain (Jones 1994; Glencross and Stuart-Macadam 2000; Lewis 2018).

Fracture patterns are also influenced by environment and social and cultural practices. Social roles may result in different environments, lifestyles, and activities, with associated differences in the risks and type of injuries (Sofaer 2006; Glencross 2011; Buzon 2012; Lewis 2018). Age is both biologically and socially determined, and life stages have an associated social and cultural significance. Biological age affects abilities and influences social age, while social practices can affect development. The meaning and range of social age categories are influenced by gender, socio-economic, and cultural background and they vary between and within populations (Sofaer 2006). Osteological age categories cannot be directly associated with a social age, but they can be used to explore patterns and interpret them within the archaeological and historical context (Sofaer 2006; Lewis 2011).

Studies of non-adult fracture patterns allow an interpretation of how fractures were sustained while associating fracture type, location, and prevalence with age and the archaeological context may reveal possible risk factors and activity patterns. It offers information to study lifestyle and social organisation and possible occupations or violence (Glencross 2011; Lewis 2014). While many trauma studies focus on abuse, studies on activities and occupations of non-adults are increasing, particularly for the medieval and post-medieval periods (Lewis 2002, 2016, 2018; Connell et al. 2012).

### *Childhood and adolescence in medieval and post-medieval Western Europe*

Life in medieval and post-medieval towns was influenced by socio-economic background, age, and gender. Towns included children from varying social classes and many children

and adolescents migrated to towns from the countryside (Shahar 1990; Hanawalt 1993; Alexandre-Bidon and Lett 1997; Heywood 2001).

Historical sources divided life into stages, which did not exactly correspond to biological development (Hanawalt 1993; Gilchrist 2012). *Infantia* (birth to 7 years) was regarded as a helpless, dependent period (Shahar 1990; Alexandre-Bidon and Lett 1997). Between 1 and 2 years old, children start to crawl, walk, and interact, which increases their risk of injury (Lewis 2007; Gilchrist 2012). Historical documents recorded various accidents, including drowning, falls, suffocation, burns, blows from animals or falling objects, violence, accidents with vehicles, ingestion of objects, and animal bites. Suffocation and fire were more common under 1 year of age, while drowning and falls were more common in older children. Accidents were recorded for all social groups, and boys were more commonly affected than girls (Hanawalt 1977; Alexandre-Bidon and Lett 1997; Sigal 1997).

*Pueritia* (7–14 years) often meant the start of education, training, or work, depending on class and gender. Children from the lower classes likely had a more extensive workload. *Adolescentia* started around 12 years in girls and 14 years in boys and could last up to 21 or 28 years old. Many children, both boys and girls, left home for education, apprenticeship, or employment. This could be as early as 7 years old, but most were probably between 10 and 30 years old (Shahar 1990; Hanawalt 1993; Alexandre-Bidon and Lett 1997; Heywood 2001).

In higher classes, boys and occasionally girls could be educated in other households, which included military training for boys, or in schools or monasteries. Most girls were raised to be wives and mothers (Shahar 1990; Alexandre-Bidon and Lett 1997; Heywood 2001). Children from the lower classes more commonly started work, for example as servants or labourers (Shahar 1990; Alexandre-Bidon and Lett 1997). Servants were a large group within urban populations and they generally came from poorer backgrounds. The type of employment or training children and adolescents received depended on socio-economic background and gender. Occupations were more limited for girls. They could be trained as artisans or shopkeepers and many girls were employed in textile or food industries or as servants. Boys could be apprenticed in varied crafts, with merchants or bankers, or they could be employed as servants or labourers. Apprenticeships were less common than employment. They could last between 2 and 3 years, and up to 10 years or more. Children and adolescents likely formed an important part of the workforce (Shahar 1990; Hanawalt 1993; Alexandre-Bidon and Lett 1997; Heywood 2001; Gilchrist 2012).

Most work performed by children was probably light and it is estimated that less than half the children under 14 years old were employed in the early modern period (Heywood 2001). Nevertheless, many children and adolescents started work, apprenticeships, or training, which exposed them to various occupational risks. Play and environment, both inside and outside the home, could also result in accidents, while some children may have been exposed to violence. From 8 to 12 years old, accident patterns in boys and girls started to resemble those in adults (Hanawalt 1977; Shahar 1990; Alexandre-Bidon and Lett 1997; Heywood 2001; Lewis 2018).

### ***A contextual study of non-adult trauma***

The study of non-adult trauma presents limitations and many fractures probably go unnoticed because new bone formation can be absent and is often greatly remodelled (Lewis

2018). Non-adults also constitute only a small part of most medieval and post-medieval assemblages (Lewis 2011; Gilchrist 2012). Socio-economic background, migration, fertility, and mortality affect the composition of the buried population. Funerary practices and social organisation affect who is buried how and where, and not all burials are preserved or excavated (Mays 1998; Sellier 2011). However, a comparison of those groups that are present can provide important information (Robb et al. 2001).

Because the presence of certain types and rates of injury can be more closely linked to age, the study of non-adult trauma allows the exploration of differences in the risk of injury between age categories. When combined with the archaeological and historical context, this offers information to interpret lifestyle, activities, and environment of non-adults in the past, which may be related to social roles. This study aimed to determine the presence of skeletal injury and analyse fracture mechanisms and patterns in non-adults from two late medieval to post-medieval urban populations from Flanders, based on macroscopic evidence as a first approach. The populations were derived from a churchyard from Mechelen and the interior of a church from Antwerp, to explore socio-economic differences.

## Material and methods

Between 1987 and 1990, excavations in the transept and presbytery of the Cathedral of Our Lady in the centre of Antwerp, Belgium, revealed almost 1000 graves. Most graves were dated between the fifteenth and eighteenth-century AD. Individuals were buried in coffins and a few were placed in crypts (Janssens and Veeckman 1992). Antwerp was an important city in the low countries and it particularly prospered in the fifteenth–sixteenth centuries. Because burial within the church was generally more expensive, the individuals likely represent the wealthier parts of the population (Harding 2002). The churchyard was not excavated. The original study included 854 individuals, and among them, 69 (8.1%) were younger than 18 years at death (Janssens et al. 1993). Sixty-one non-adults were reanalysed to estimate age and determine the presence of fractures and dislocations.

The northern churchyard of St. Rombout's Cathedral in Mechelen, Belgium, was partially excavated between 2009 and 2011. The excavation revealed 4158 individual depositions, and 351 from the parish cemetery were studied in detail. The burials were dated between the late tenth and eighteenth centuries AD and consisted of plain earth and coffin burials, including single, collective, and multiple burials. The churchyard likely included mainly parish inhabitants from the middle and lower classes (Harding 2002). St. Rombout's parish lies in the centre of Mechelen and was one of the wealthier, more urbanised areas. Mechelen was also a relatively important town, particularly in the fifteenth–sixteenth centuries. Only a few burials were excavated within the church (Depuydt, Kinnaer, and Van de Vijver 2013). The detailed study included 235 individuals from the fifteenth–eighteenth-century layers, among whom 74 were younger than 18 years old (31.4%) (Van de Vijver 2018, 2019).

Overall, 135 non-adults, including 61 from the church assemblage from Antwerp and 74 from the churchyard assemblage from Mechelen, were analysed for this study.

Preservation was based on an estimation of completeness, fragmentation, and surface wear and the presence of each bone was recorded to analyse the true prevalence. Non-adult age-at-death was based on the degree of dental formation (Moorrees, Fanning, and Hunt 1963a, 1963b), epiphyseal fusion, and diaphyseal length (Scheuer and

Black 2000). Individuals were placed in age categories based on developmental age, including perinates (0–1 month), infants (1–11 months), 1–5 years, 6–11 years, and 12–17 years. Sex was not estimated because it is inaccurate for immature individuals (Lewis 2007).

Macroscopic changes that could indicate fractures or dislocations were based on the presence of a callus or localised new bone formation, abnormal shape of bones, bone destruction, or differences in size. Descriptions included skeletal element, side and location on the bone, the extent, orientation, and appearance of the changes, indications for malunion or secondary changes, and evidence of healing and remodelling (Lovell 1997). Where possible, bones were compared to the other side to observe differences in morphology. All possible indications for fractures were included, along with possible diagnoses (Table 1).

Prevalence rates were compared overall, across age categories and between sites. Because non-adult fractures heal and remodel rapidly, and because development influences type and risk of injury, comparisons were also made within the different age categories. All non-adult individuals were included to provide a comprehensive picture. Comparisons between sites and age categories to analyse overall differences in fracture prevalence were made using crude prevalence, based on number of individuals, although the completeness of individuals was also considered. True prevalence, based on the preservation of particular skeletal elements (Roberts and Cox 2003, 20), was calculated for the observed fracture types, to compare prevalence of certain types between sites and among age groups.

Differences were explored through statistical analyses, using SPSS Statistics 20 (IBM, New York, United States). Contingency tables and Pearson's  $\chi^2$  or Fisher's exact test were used to test associations for nominal scale variables and the Kolmogorov–Smirnov test was used for ordinal scale variables. Associations were considered significant when  $p < 0.050$ .

## Results

### *Preservation and age composition*

The individuals from Antwerp were less complete than those from Mechelen (Figure 1(a)). This is also related to sampling strategy, the individuals from Antwerp included all non-adults, while those from Mechelen were part of a sample based on completeness of the grave. Only 22 individuals (36.1%) from Antwerp had more than 50% of their skeleton preserved compared to 65 (87.8%) from Mechelen. Surface wear varied between limited and more extensive changes in Mechelen. In Antwerp, surface wear was generally limited, which allowed a comprehensive observation of potential lesions. Fragmentation was limited to relatively severe for both sites.

Age composition differed between Antwerp and Mechelen (Figure 1(b) and Table 2). The proportion of non-adults within the overall assemblage was higher in Mechelen (31.4%) compared to Antwerp (8.1%). The distribution across age categories also varied. The proportion of individuals under 12 years old was higher in Antwerp, and most were between 1 and 5 years of age. In Mechelen, most non-adults were between 12 and 17 years of age. This difference in age distribution is significant according to the Kolmogorov–Smirnov test ( $p < 0.001$ ).



**Table 1.** Overview of individuals with indications for skeletal injury, including age, degree of completeness, and a description of the observed changes.

Site	Individual	Age (years)	Preservation	Description of the changes
<i>Cathedral of Our Lady, Antwerp</i>	GR35-SK207	3–5	50–75%	Localised thickening on the external surface of the antero-lateral shaft of a right upper rib.
	GR553-SK736	7–8	50–75%	Localised thickening at the distal third of the diaphysis of the left fibula, surrounding the bone. The left tibia was absent.
<i>St. Rombout's churchyard, Mechelen</i>	169-2	12–16	50–75%	The right ulna showed posterior and medial bowing of the distal diaphysis; The left radius showed posterior bowing of the middle diaphysis. The changes were not associated with new bone formation and there were no changes in the right radius or left ulna.
	170-4	15–17	>75%	An indeterminate lumbar vertebra showed a porous depression in the anterior marginal area of the articular surface of the body.
	183-1	15–17	50–75%	An indeterminate rib showed a decreased antero-posterior and supero-inferior width in the lateral area of the shaft, with an abnormal 'pinched' appearance.
	225-2	11–16	>75%	A small fragment, resembling dental material, was embedded in the alveolar bone of the right mandible between the 2nd premolar and 1st permanent molar.
	227-3	14–18	>75%	Detachment of the apex and an area of cortical bone of the auricular surface of the right ilium. The fragment is unfused, with irregular bone growth along the margins and a porous, irregular fracture surface.
	268-1	16–18	>75%	A small fragment was detached from the lingual surface of the left 1st maxillary incisor, the margins were rounded.
	275-6	16–17	50–75%	The 9th thoracic vertebra showed a large lamellar depression with regular margins, which covered almost half the articular surface on the left side. The 10th thoracic vertebra showed slight, associated changes.
	275-8	16–17	50–75%	The body of the 5th thoracic vertebra showed lateral wedging.
	287-4	16–17	>75%	Localised lamellar thickening on the posterior surface of the distal third of the left fibular diaphysis. The surface is irregular. The long bones of the lower limbs also showed widespread and diffuse periosteal new bone formation; The frontal bone showed a lamellar, circular depression with a smooth surface, just right to the central area (c. 15mm diameter).
	287-7	14–17	50–75%	The 5th lumbar vertebra showed a slight depression and pitting at the anterior marginal area of the inferior surface.
	319-1	1–2	50–75%	The proximal physal surface of the left radius showed a small osteolytic lesion in the central area with porous new bone formation.
	324-4	16–17	>75%	An indeterminate thoracic vertebra showed anterior wedging of the body and a slight depression and pitting of the anterior marginal area of the articular surface; There was a fracture line and partial separation between the body and the lateral tubercle of the right talus, with slight superior displacement of the tubercle.

*(Continued)*



**Table 1.** Continued.

Site	Individual	Age (years)	Preservation	Description of the changes
	324-7	16–17	>75%	The left ischial epiphysis, which is partly fused, showed an incomplete, transverse fracture line in the central, lateral area. The fracture line is mostly closed. There are no changes on the ischium; The right 3rd metatarsal showed an enlarged middle diaphysis.
	361-1	16–17	50–75%	The anterior inferior iliac spine of the left ilium showed irregular new bone growth and exostoses on the anterior and posterior surface and a fracture line on the transition to the iliac blade. The fragment was slightly displaced.
	424-1	15–17	50–75%	The right frontal bone showed a lamellar oval depression (c. 25x15mm), with an irregular surface.
	483-1	13–17	>75%	The 5th lumbar vertebra showed minor posterior wedging of the body.

### *Cathedral of Antwerp*

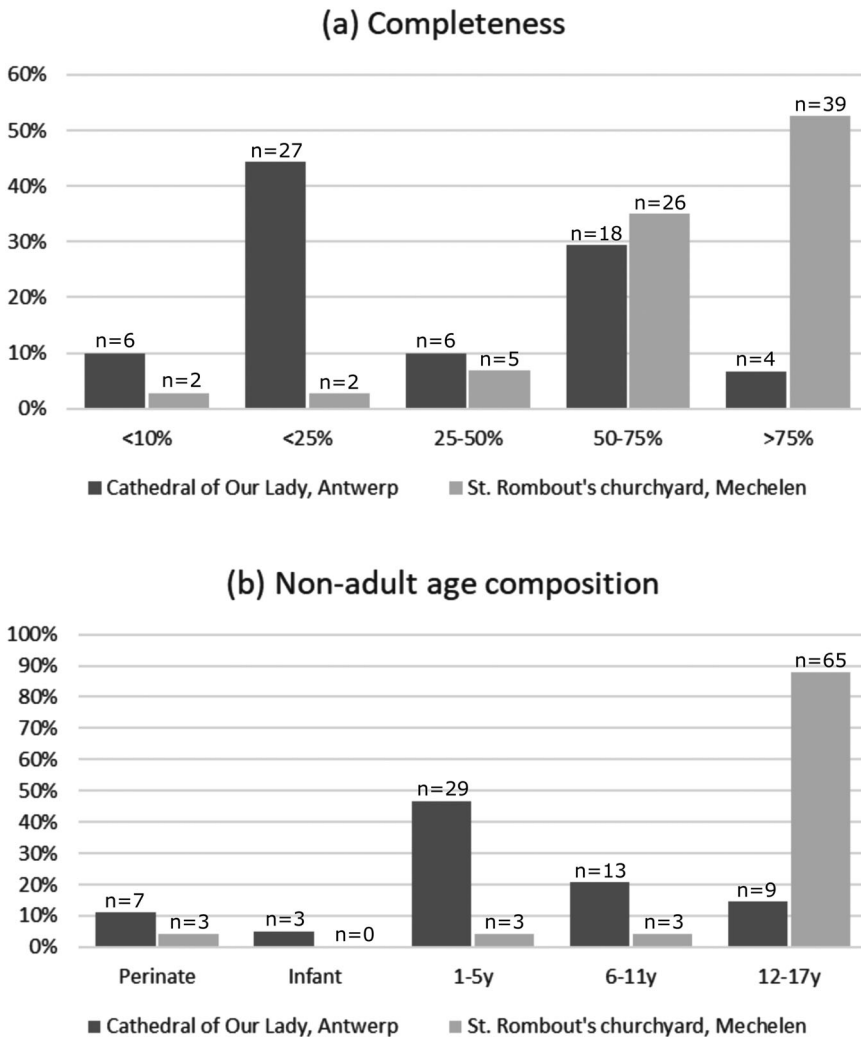
Two non-adults from Antwerp showed indications for a fracture (crude prevalence, 3.3%; [Tables 1](#) and [2](#)). The left fibula of GR553-SK736 (3–5 years) showed possible callus formation, which indicated a complete fracture ([Figure 2](#)). Possible callus formation on a right upper rib of GR35-SK207 (7–8 years) suggests an incomplete fracture. Other possible diagnoses for both lesions include periosteal new bone formation, which can be related to varied conditions such as inflammation, infection, trauma, metabolic or vascular conditions, or neoplasms (an abnormal growth of tissue) ([Waldron 2009](#)), but the localised appearance suggests trauma. Lesions resembling fracture calluses on ribs may also occur in thalassaemia (a genetic form of anaemia) and these can potentially be confused ([Lewis 2012](#)). However, because the disease is mostly found around the Mediterranean ([Aufderheide and Rodríguez-Martín 1998](#), 347), trauma is more likely in this population.

Calculation of the true prevalence showed a rate of 3.6% for the left fibula and 0.3% for all recorded long bones in this assemblage. Additionally, 2.4% of individuals for whom ribs were preserved presented a lesion and a lesion was observed on 0.2% of all recorded ribs ([Table 3](#)). There was no significant association with age.

### *St. Rombout's Churchyard, Mechelen*

Sixteen individuals from Mechelen (21.6%) showed possible indications for fractures, and four individuals presented multiple lesions ([Tables 1](#) and [2](#)).

Three non-adults showed possible long bone injuries. Individual 169-2 showed abnormal bowing of the right ulna and left radius ([Figure 3](#)), which may be related to permanent bowing deformation. Osteogenesis imperfecta (a genetic disorder), rickets (related to vitamin-D deficiency), or post-mortem damage are unlikely because no other long bones were bowed. Localised new bone formation on the left fibula of 287-4 suggests trauma and may be related to a crush or incomplete fracture. Widespread periosteal new bone formation across the lower limbs may be secondary changes or may not be related. The left radius of 319-1 showed a possible injury on the proximal physal



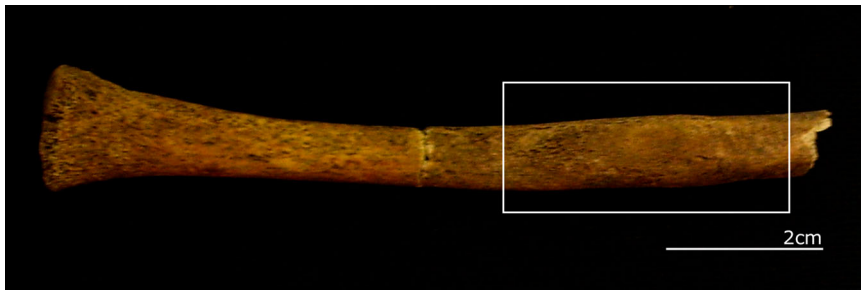
**Figure 1.** Histogram illustrating (a) the degree of completeness of individuals and differences between the sites; and (b) the distribution of non-adult individuals across age categories for both assemblages (Cathedral of Our Lady, Antwerp:  $N=61$  and St. Rombout's cemetery, Mechelen:  $N=74$ ).

surface (Figure 4). The epiphysis and right radius were absent, but the localised changes suggest trauma.

Three individuals showed possible injuries of the coxal bone. In 324-7, an incomplete fracture line on the ischial epiphysis suggests a physeal injury. Considering the location, variation seems unlikely. In 227-3, the apex of the right auricular surface (for the articulation with the sacrum) was detached and the porous surface and marginal bone growth suggested an avulsion fracture, caused by force placed on a tendon or ligament (Lovell 1997), with delayed or non-union. Individual 361-1 showed a likely avulsion injury of the left anterior inferior iliac spine, which could be a physeal injury. The callus and fracture line indicate a complete fracture, with slight displacement (Figure 5).

**Table 2.** Overview of the overall crude prevalence rate of skeletal lesions for both sites, for the different age categories and different degrees of completeness. Results of the  $\chi^2$  test to determine significant differences between both sites are included.

		Perinate	Infant	1–5y	6–11 years	12–17 years	Total	$\chi^2$ -test
All individuals	Cathedral of Our Lady, Antwerp	0/7	0/3	1/29 (3.4%)	1/13 (7.7%)	0/9	2/61 (3.3%)	$\chi^2=9.736$ , df=1, $p=.002$
	St. Rombout's churchyard, Mechelen	0/3	0/0	1/3 (33.3%)	0/3	15/65 (23.1%)	16/74 (21.6%)	
Individuals preserved >10%	Cathedral of Our Lady, Antwerp	0/7	0/2	1/24 (4.2%)	1/13 (7.7%)	0/9	2/55 (3.6%)	$\chi^2=8.855$ , df=1, $p=.003$
	St. Rombout's churchyard, Mechelen	0/3	0/0	1/3 (33.3%)	0/3	15/63 (23.8%)	16/72 (22.2%)	
Individuals preserved >25%	Cathedral of Our Lady, Antwerp	0/6	0/1	1/8 (12.5%)	1/11 (9.1%)	0/2	2/28 (7.1%)	$\chi^2=3.294$ , df=1, $p=.070$
	St. Rombout's churchyard, Mechelen	0/2	0/0	1/3 (33.3%)	0/3	15/62 (24.2%)	16/70 (22.9%)	
Individuals preserved >50%	Cathedral of Our Lady, Antwerp	0/5	0/1	1/6 (16.7%)	1/8 (12.5%)	0/2	2/22 (9.1%)	$\chi^2=2.414$ , df=1, Fisher's exact test: $p=.142$
	St. Rombout's churchyard, Mechelen	0/2	0/0	1/3 (33.3%)	0/3	15/57 (26.3%)	16/65 (24.6%)	



**Figure 2.** Left fibula of GR553-SK736 (Antwerp), which showed an enlarged area of bone, possibly a fracture callus.

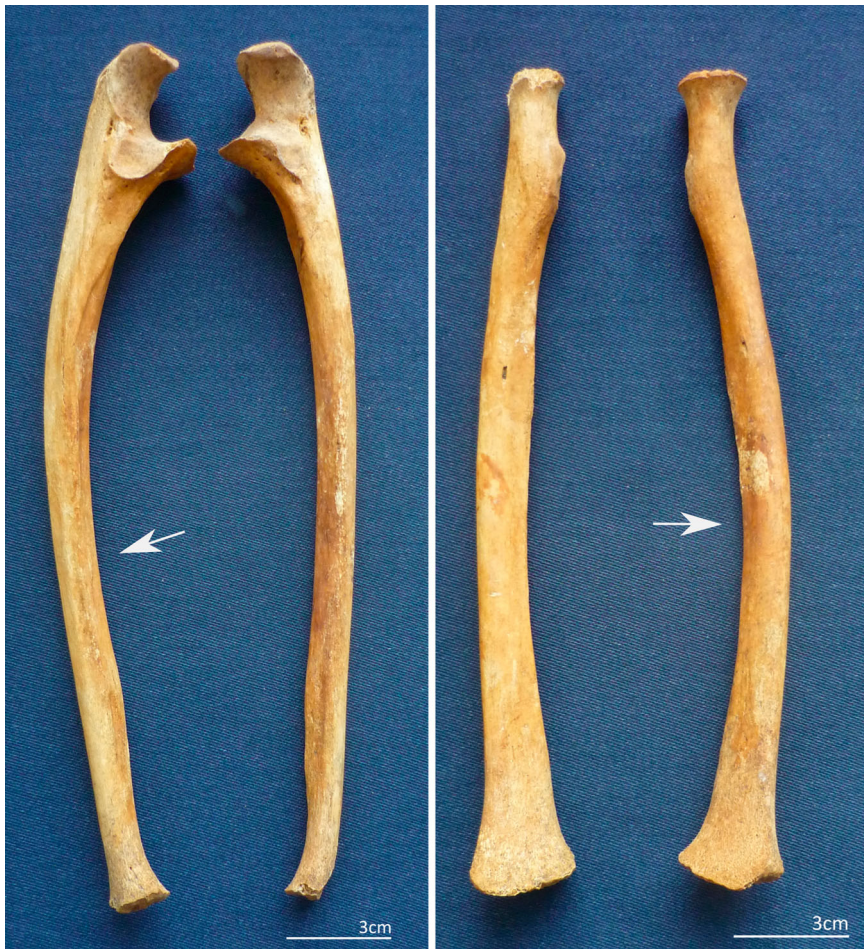Two individuals showed possible foot injuries. In 324-4, a fracture line in the posterior right talus indicated a Shepherd's fracture, which can be caused by avulsion. A minor displacement suggests that it was not an anomaly. Individual 324-7 showed an enlarged middle diaphysis of a right metatarsal, which may indicate a complete fracture.

Two individuals showed a depression on the frontal bone (287-1 and 324-4), which was associated with a healed depressed fracture (Figure 6). The lamellar, smooth surface indicates ante-mortem changes. Neither was located along the central metopic line, which could suggest possible developmental anomalies. Two individuals showed possible dental trauma. An upper incisor of 268-1 showed a detached fragment with rounded margins, indicating ante-mortem damage. In 225-2, an embedded fragment in the mandible resembled a root fragment and may be related to the fracture of a deciduous tooth. An odontoma or tumour related to dental development is another possible diagnosis (Ortner 2003).

Six individuals showed possible traumatic lesions in vertebrae. Individuals 275-8 and 483-1 showed slight wedging of a vertebral body, which may be related to compression trauma (Lovell 1997). The changes were not associated with Schmorl's nodes (impressions related to herniation of the intervertebral disc) and there was no anterior wedging, suggesting that they were not associated with Scheuermann's disease (a developmental disorder of the spine) (Ortner 2003). Developmental anomalies are unlikely because the

**Table 3.** Overview of the true prevalence per skeletal element. For ribs, vertebrae, and teeth, the prevalence considers those individuals where these elements could be observed.

	Cathedral of Our Lady, Antwerp	St. Rombout's churchyard, Mechelen
Left radius	0/25	2/61 (3.3%)
Right ulna	0/26	1/59 (1.7%)
Left fibula	1/28 (3.6%)	1/54 (1.8%)
<b>Total number of long bones</b>	<b>1/344 (0.3%)</b>	<b>4/834 (0.5%)</b>
Right pelvis	0/33	1/67 (1.5%)
Left pelvis	0/36	2/63 (3.2%)
<b>Total number of limb bones</b>	<b>1/479 (0.2%)</b>	<b>9/1159 (0.8%)</b>
Foot	0/25	2/47 (4.3%)
<b>Rib</b>	<b>1/560 (0.2%)</b>	<b>1/1051 (0.1%)</b>
<b>Ribs (individuals)</b>	<b>1/41 (2.4%)</b>	<b>1/67 (1.5%)</b>
<b>Cranial vault</b>	<b>0/37</b>	<b>2/54 (3.7%)</b>
<b>Teeth (individuals)</b>	<b>0/37</b>	<b>2/51 (3.9%)</b>
<b>Vertebral bodies (individuals)</b>	<b>0/35</b>	<b>6/71 (8.5%)</b>



**Figure 3.** Possible plastic bowing deformation in the right ulna and left radius of 169-2 (Mechelen).

changes were observed in only one vertebra and only in bodies, although variation is possible. Individual 275-6 showed a large lamellar depression on the inferior body of a thoracic vertebra. Considering the extent, the changes could indicate a fracture (Maat and Mastwijk 2000). In three individuals (170-4, 287-7, and 324-4) a vertebral body showed an anterior porous depression on the articular surface (Figure 4). The porous surface suggests that Schmorl's nodes are unlikely and there were no indications for post-mortem damage. Although the unfused annular rings were absent, the lesions could indicate epiphyseal injuries, which are often accompanied by anterior impression fractures (Maat and Mastwijk 2000).

An indeterminate right rib of 183-1 showed a 'pinched' appearance, without indication for a callus or fracture line (Figure 5). The absence of periosteal new bone formation and osteolytic (loss of bone) lesions suggests that infection is unlikely. The lesion may be associated with an injury with secondary bone resorption.





**Figure 4.** Possible injury on the proximal physal surface of the left radius of 319-1 (Mechelen) (left), and a possible traumatic lesion of the vertebral endplate in a lumbar vertebra of 170-4 (Mechelen) (right).

Lesions in limb bones (10.7% of individuals) were more common than cranial lesions (3.7%), with a higher prevalence in the lower (6.7%) compared to the upper limb (2.7%). The true prevalence rates were relatively low, between 1.5% and 8.5% (Table 3). Vertebral lesions were relatively common (8.5%), while rib lesions were the least frequent among the lesions. Possible injuries to vertebral endplates were the only lesions observed in more than two individuals. Overall, 0.5% of all recorded long bones and 0.1% of all recorded ribs showed a possible injury. One lesion, the likely physal injury on the left radius of 319-1, was observed in a younger individual between 1 and 5 years old (Table 2). All other changes were observed in individuals between 12 and 17 years. Possible physal injuries, in vertebrae and coxal bones, were also observed between 12 and 17 years old. There was no significant association with age.

### *Comparisons between Antwerp and Mechelen*

Overall, more non-adults from Mechelen than Antwerp showed possible skeletal injuries, which was significant (Table 2). The higher prevalence in Mechelen remained significant when only individuals with more than 10% of their skeleton preserved were considered. When only individuals with more than 25% of their skeleton preserved were included, the sample size for Antwerp decreased considerably and the difference was no longer significant, although the prevalence was still higher in Mechelen. Similar patterns were observed for individuals with more than 50% of their skeleton preserved.


Lesions were not observed in individuals under 1 year of age (Table 2). In Antwerp, lesions were only observed in individuals under 12 years of age and in Mechelen, most lesions were observed between 12 and 17 years of age. Lesions were observed in one



**Figure 5.** Avulsion injury with displacement of the anterior inferior iliac spine of the left ilium of 361-1 (Mechelen) (top). A right rib of 183-1 (Mechelen), with a 'pinched' appearance, which may be associated with necrosis that resulted from an injury (bottom).

individual between 1 and 5 years in Mechelen (33.3%) and one from Antwerp (3.4%), but this difference was not significant ( $\chi^2=4.144$ ,  $df = 1$ , Fisher's exact test:  $p = 0.181$ ). Fractures were not observed in individuals between 6 and 11 years from Mechelen, but fractures were recorded in one individual (7.7%) from Antwerp, which was also not significant ( $\chi^2=0.246$ ,  $df = 1$ , Fisher's exact test:  $p = 1.000$ ). In Mechelen, the highest prevalence was observed between 12 and 17 years old (23.1%), while fractures were not observed in any of the nine individuals within this age category from Antwerp, but this was also not significant ( $\chi^2=2.605$ ,  $df = 1$ , Fisher's exact test:  $p = 0.189$ ). Patterns were similar for individuals with more than 10% or 25% of their skeleton preserved.





**Figure 6.** Frontal bone of 424-1 (Mechelen) with a healed depressed fracture.

Possible physéal injuries were only observed in Mechelen. Both sites showed a fracture of a fibula and a rib, with a higher true prevalence in Antwerp. When all recorded long bones were considered, the prevalence was higher in Mechelen.

## Discussion

Both sites showed evidence for skeletal trauma, including typical non-adult injuries, with differences between sites and possible age-related patterns. Differences in age composition between sites were considered, as they influenced comparisons.

The assemblage from Mechelen showed a higher proportion of non-adults (31.4%) than Antwerp (8.1%) and age distribution differed significantly. Antwerp showed a higher proportion of individuals under 12 years old, compared to Mechelen where most non-adults were between 12 and 17 years old. This may be related to their socio-economic background. The individuals from Antwerp were buried inside the cathedral, which is a more expensive location, and they may have belonged to higher and wealthier classes (Janssens and Veeckman 1992; Harding 2002). Their low overall number may indicate spatial patterns based on age or poor preservation (Lewis 2007). The burials from Mechelen were excavated from the churchyard, which mostly included middle and lower classes (Harding 2002). Individuals under 26 years old were also more commonly buried in plain earth and plural burials, which suggests a poorer socio-economic background (Van de Vijver 2018, 2019). The strong presence of adolescents may reflect a high mortality in this age group. This has been observed in other urban cemeteries and is sometimes associated with a strong presence in the living population and occupational risks and exposure to disease (Lewis 2002; Connell et al. 2012). Despite underrepresentation, comparisons within age categories are more useful to observe injury patterns, which are strongly influenced by age, with distinct types in non-adults.

Overall 22 lesions from both sites may indicate skeletal injuries. Peri-mortem fractures or dislocations were not observed. Aetiology was not always straightforward. In several individuals, the identification was based on localised new bone formation. While periosteal

new bone can be related to various conditions (Waldron 2009), localised lesions are more suggestive of trauma, although neoplasms may also result in localised new bone formation. Although rib lesions in thalassaemia can be confused with rib fractures, this seems unlikely for this assemblage. The embedded dental material in a mandible from Mechelen may be related to trauma or an odontoma (Ortner 2003).

Four individuals showed lesions in long bones. Changes in a fibula from Antwerp may indicate a complete transverse fracture, which suggests direct trauma, or an oblique fracture, which is caused by indirect angular or rotational forces (Lovell 1997). The fibular lesion from Mechelen could indicate an incomplete fracture, related to indirect trauma and bending forces, or a crush fracture resulting from direct trauma (Lovell 1997). These lesions could indicate accidents, such as a fall or a stumble, or a blow. Plastic bowing deformation was observed in both forearms of one individual and it is often associated with falling on outstretched hands (Borden 1974). The physal lesion in a radius suggests indirect compression, also possibly from a fall. Because the epiphysis was absent, it was not possible to classify this injury according to the Salter–Harris scheme.

Injuries to coxal bones were observed in three individuals from Mechelen. A possible fracture of the ischial epiphysis indicated direct trauma, perhaps resulting from a fall, and this may represent a Salter–Harris type III injury. Two avulsion fractures indicate indirect trauma. Two individuals from Mechelen showed injuries to the foot. A Shepherd's fracture indicates avulsion or indirect trauma resulting from inversion or forced plantar flexion of the foot, e.g. during stumbling or falling. A possible complete metatarsal fracture may be related to a direct impact (Lovell 1997), which indicates a fall or blow.

Depressed cranial fractures were observed in two individuals from Mechelen. They result from direct trauma to the head, which is often associated with a blow (Ortner 2003). They may indicate violence, but they could also be accidental. Two individuals showed possible dental trauma, but the mechanisms were unclear.

A possible rib fracture from Antwerp could indicate a direct force to the ribcage, which occurred through a fall or blow (Lovell 1997). The rib lesion from Mechelen is unusual, but it may indicate necrosis as a result of the injury. Lesions in vertebral bodies were observed in six individuals from Mechelen and are related to indirect trauma. Three possible vertebral body fractures indicate vertical forces on the spine (Lovell 1997; Maat and Mastwijk 2000). Three possible injuries of annular epiphyses are typical growth injuries, which are caused by hyperflexion (Maat and Mastwijk 2000).

Most injuries from both sites suggest accidental trauma, such as falls. The vertebral lesions in Mechelen could indicate falls, but also regular mechanical stress on the spine. A few long bone injuries and the rib and cranial lesions may indicate a blow, but they could also result from falls or accidents. Four individuals from Mechelen showed multiple lesions (Table 1). In 169-2, the changes may be related to the same impact, but it is unclear whether the lesions in the other individuals are related to one or more incidents.

A few limited complications were observed in Mechelen. Malunion included minor displacements in two, and delayed or non-union in one, avulsion injury. The rib lesion showed possible necrosis, which could indicate damage to the blood supply. It is unclear whether the widespread periosteal new bone formation in the individual with possible fibular trauma is related to the injury, which would indicate secondary infection.

The distribution across the body showed that limb bone fractures, with a higher prevalence in the lower limb, were most common in Mechelen, followed by spinal injuries. Only

two lesions were observed in Antwerp, but both the possible rib and fibula fracture showed a higher true prevalence compared to Mechelen. Possible physal injuries were only recorded in Mechelen and most were observed between 12 and 17 years of age. This could be related to the increased ossification of epiphyses in older individuals (Glen-cross and Stuart-Macadam 2000).

Crude prevalence was significantly higher in Mechelen (21.6%) compared to Antwerp (3.3%). The incompleteness of individuals from Antwerp may have affected prevalence, but the patterns remained similar, although not significant, for more complete individuals. Lesions were only observed under 12 years of age in Antwerp, while in Mechelen, individuals between 12 and 17 years showed the highest prevalence. There were no significant associations with age or significant differences between sites within the age categories. The younger age categories showed only limited differences, although only a few individuals younger than 12 years old were recorded in Mechelen. Differences were more apparent in the 12–17-year-old group, although this category was not well represented in Antwerp. While 23.1% of the 12–17-year-olds from Mechelen showed possible injuries, none were observed in Antwerp. Vertebral lesions were also relatively common in Mechelen, but none were recorded for Antwerp.

Incomplete preservation hindered the observation of skeletal lesions and likely affected the prevalence. The low prevalence hindered the observation of patterns and significant differences in fracture types between the sites and age categories.

Although differences were not significant, it seems that non-adults from Mechelen, particularly between 12 and 17 years old, were more exposed to risks of skeletal injury. This may be related to their activities. Historical studies indicate that many children and especially adolescents in medieval and post-medieval towns were employed or training as apprentices, particularly from the lower and middle classes. The differences between the sites may reflect a different exposure to injury and mechanical stress, which may be related to socio-economic background. More limited differences in age categories under 12 years old suggest that patterns may have had less impact on younger individuals. In Mechelen, the prevalence increased between 12 and 17 years and although this was not significant, it may suggest an increased risk of injury. Historical studies indicate that at around 12–14 years, many individuals started to work and a census from 1796 in Mechelen recorded employment for 25% of the 12–14-year-olds (Piessens 2014). The rapid healing and remodelling of fractures, particularly in young children, and a longer period of exposure in older individuals may have influenced this pattern, although the relatively strong increase suggests that activity patterns could have been important. Most lesions can be related to accidental injuries, while the relatively high prevalence of vertebral lesions suggests that mechanical stress and occupational risks may also have been important.

Comparisons with other populations are hindered by the low number of studies on non-adult trauma. The non-adults from St. Mary Spital in London showed a crude prevalence rate of 3.2% for skeletal trauma. This site also showed a high number of adolescents. Only individuals over 6 years old showed evidence of fractures, with a higher prevalence in adolescents. There were also many spinal injuries and lower limbs showed more fractures than upper limbs, although the differences were limited (Connell et al. 2012). A study on urban compared to rural populations from England showed a fracture prevalence of 4.0% between 6 and 17 years and showed a gradual increase with age. The skull was most commonly affected, but the lower limbs also showed a slightly higher number of lesions

compared to the upper limbs. Spinal injuries were observed, but they were less common (Lewis 2016). The prevalence in Mechelen was, therefore, relatively high, although it should be considered that all possible lesions were included in this study, and not just clear examples. Prevalence in Antwerp was relatively low. A study of different sites across London showed a lack of lesions in high-status cemeteries, while changes were recorded for lower-status cemeteries, which resembles the differences between Mechelen and Antwerp (Redfern 2017). The increase with age in Mechelen and a higher prevalence in adolescents was also observed in St. Mary Spital and the study on urban compared to rural sites (Lewis 2016; Redfern 2017).

## Conclusion

Despite the limitations associated with studying non-adult skeletal injuries, several indications for fractures were observed in the assemblages from Antwerp and Mechelen. The lesions included possible complete and incomplete fractures; depressed, compression, and avulsion fractures; and several physal injuries. The study provided examples of both typical growth injuries and fracture types which are also observed in adults. The low number of individuals and low prevalence of fractures hindered the observation of significant differences across age categories and between assemblages, although a few patterns could be observed.

The differences in age distribution, with a higher proportion between 12 and 17 years in Mechelen and a higher proportion under 12 years old in Antwerp, are likely related to the socio-economic background. The individuals from Mechelen, particularly those between 12 and 17 years old, showed a higher prevalence of possible skeletal injuries compared to Antwerp, which may indicate differential risks of injury that are possibly related to different social roles. Differences between younger age categories were limited, and perhaps these age groups showed less variation in activity patterns. There was a higher prevalence in older non-adults from Mechelen, who also showed a relatively higher prevalence of vertebral injuries, which may indicate mechanical stress and occupational risks.

The study provides a picture of possible non-adult trauma in urban populations in late medieval and post-medieval Flanders, with indications for age-related patterns and socio-economic differences. Future perspectives include the use of radiography for additional diagnoses and more detailed interpretations of the lesions. Comparisons of fracture patterns between adult individuals from both assemblages would offer additional information on socio-economic differences and age-related patterns. Increasing the sample size could provide significant patterns to interpret differences between social groups and age categories.

## Notes on contributors

*Katrien Van de Vijver* currently works as a researcher at the Royal Belgian Institute of Natural Sciences in Brussels, Belgium, studying human remains from archaeological excavations in Brussels and Flanders. She completed her doctorate at the Center for Archaeological Sciences, KU Leuven, in 2017. Her PhD research concerned the contextual study of the human remains from the medieval and post-medieval St. Rombout's cemetery in Mechelen, Belgium, integrating the archaeological context in the analysis of the skeletal data to obtain more detailed and nuanced interpretations on past social organisation and lifestyle.

## Acknowledgements

The data from Antwerp were collected for my dissertation for an MSc in Human Osteology and Funerary Archaeology (University of Sheffield, UK), under the supervision of Dr Andrew Chamberlain and Dr Pia Nystrom. The data on Mechelen were collected as part of my PhD research, funded by the Center for Archaeological Sciences (University of Leuven, Belgium), under the supervision of Dr Wim Van Neer and Dr Ronny Decorte. The Archaeology Departments of the city of Antwerp and the city of Mechelen provided access to the material and much valued support. I would also like to thank Caroline Polet, Mary Lewis, and Petra Verlinden for their feedback and the reviewers for their comments to improve this paper.

## Disclosure statement

No potential conflict of interest was reported by the author.

## References

- Alexandre-Bidon, D., and D. Lett. 1997. *Les enfants au Moyen Âge. Ve-XVe siècles*. Paris: Hachette Littératures.
- Aufderheide, A. C., and C. Rodríguez-Martín. 1998. *The Cambridge Encyclopedia of Human Paleopathology*. Cambridge: Cambridge University Press.
- Borden, S. IV. 1974. "Traumatic Bowing of the Forearm in Children." *Journal of Bone and Joint Surgery* 56 (3): 611–616.
- Buzon, M. R. 2012. "The Bioarchaeological Approach to Paleopathology." In *A Companion to Paleopathology*, edited by A. Grauer, 58–76. Chichester: Wiley-Blackwell.
- Connell, B., A. G. Jones, R. Redfern, and D. Walker. 2012. *A Bioarchaeological Study of Medieval Burials on the Site of St. Mary Spital. Excavations at Spitalfields Market, London E1, 1991–2007, MOLA Monograph 60*. London: Museum of London Archaeology.
- Depuydt, S., F. Kinnaer, and K. Van de Vijver. 2013. *In de schaduw van de toren. Resultaten van het archeologisch onderzoek van het Sint-Romboutskerkhof in Mechelen (basisrapportage)* (Unpublished Report). Mechelen: Dienst Archeologie Stad Mechelen.
- Gilchrist, R. 2012. *Medieval Life. Archaeology and the Life Course*. Woodbridge: The Boydell Press.
- Glencross, B. A. 2011. "Skeletal Injury Across the Life Course." In *Social Bioarchaeology*, edited by S. C. Agarwal and B. A. Glencross, 390–409. Chichester: Wiley-Blackwell.
- Glencross, B., and P. Stuart-Macadam. 2000. "Childhood Trauma in the Archaeological Record." *International Journal of Osteoarchaeology* 10: 198–209.
- Hanawalt, B. A. 1977. "Childrearing among the Lower Classes of Late Medieval England." *The Journal of Interdisciplinary History* 8 (1): 1–22. doi:10.2307/202593.
- Hanawalt, B. 1993. *Growing up in Medieval London. The Experience of Childhood in History*. Oxford: Oxford University Press.
- Harding, V. 2002. *The Dead and the Living in Paris and London 1500–1670*. Cambridge: Cambridge University Press.
- Heywood, C. 2001. *A History of Childhood. Children and Childhood in the West from Medieval to Modern Times*. Cambridge: Polity.
- Janssens, P. A., A. Marčsik, C. de Meyere, and C. Hänsch. 1993. "Het antropologisch en paleopathologisch onderzoek." In *De Onze-Lieve-Vrouwe Kathedraal van Antwerp*, edited by W. Aerts, 338–343. Antwerp: Mercatorfonds.
- Janssens, P. A., and J. Veeckman. 1992. "Doden uit de kathedraalbodem: Antropologisch en paleopathologisch onderzoek." In *Blik in de bodem: Recent stadsarcheologisch onderzoek in Antwerp*, edited by J. Veeckman, 113–120. Antwerp: H. Nieuwdorp.
- Jones, E. 1994. "Skeletal Growth and Development as Related to Trauma." In *Skeletal Trauma in Children*, edited by N. E. Green and M. F. Swiontkowski, 1–17. London: W.B. Saunders.
- Judd, M. A., and R. Redfern. 2012. "Trauma." In *A Companion to Palaeopathology*, edited by Anne L. Grauer, 359–379. Chichester: Wiley-Blackwell.

- Lewis, M. 2002. "Impact of Industrialization: Comparative Study of Child Health in Four Sites from Medieval and Postmedieval England (AD 850–1859)." *American Journal of Physical Anthropology* 119: 211–223. doi:10.1002/ajpa.10126.
- Lewis, M. 2007. *The Bioarchaeology of Children. Perspectives from Biological and Forensic Anthropology*, Cambridge Studies in Biological and Evolutionary Anthropology. Cambridge: Cambridge University Press.
- Lewis, M. 2011. "The Osteology of Infancy and Childhood: Misconceptions and Potential." In *(Re)thinking the Little Ancestor: New Perspectives on the Archaeology of Infancy and Childhood*, edited by M. Lally and A. Moore, 1–13. Oxford: Archaeopress.
- Lewis, M. E. 2012. "Thalassaemia: Its Diagnosis and Interpretation in Past Skeletal Populations." *International Journal of Osteoarchaeology* 22 (6): 685–693. doi:10.1002/oa.1229.
- Lewis, M. 2014. "Sticks and Stones. Exploring the Nature and Significance of Child Trauma in the Past." In *The Routledge Handbook of the Bioarchaeology of Human Conflict*, edited by C. Knüsel and M. J. Smith, 39–63. Abingdon: Routledge.
- Lewis, M. 2016. "Work and the Adolescent in Medieval England AD 900–1550: The Osteological Evidence." *Medieval Archaeology* 60 (1): 138–171. doi:10.1080/00766097.2016.1147787.
- Lewis, M. 2018. *Paleopathology of Children. Identification of Pathological Conditions in the Human Skeletal Remains of Non-adults*. London: Academic Press.
- Lovell, N. C. 1997. "Trauma Analysis in Paleopathology." *Yearbook of Physical Anthropology* 40: 139–170. doi:10.1002/(SICI)1096-8644(1997)25+(139::AID-AJPA6 > 3.0.CO;2-%23.
- Maat, G. J. R., and R. W. Mastwijk. 2000. "Avulsion Injuries of Vertebral Endplates." *International Journal of Osteoarchaeology* 10: 142–152. doi:10.1002/(SICI)1099-1212(200003/04)10:2(142::AID-OA519 > 3.0.CO;2-L.
- Mays, S. 1998. *The Archaeology of Human Bones*. London: Routledge.
- Moorrees, C. F. A., E. A. Fanning, and E. E. Hunt. 1963a. "Age Variation of Formation Stages for Ten Permanent Teeth." *Journal of Dental Research* 42: 1490–1502. doi:10.1177/00220345630420062701.
- Moorrees, Coenraad F. A., E. A. Fanning, and E. E. Hunt. 1963b. "Formation and Resorption of Three Deciduous Teeth in Children." *American Journal of Physical Anthropology* 21: 205–213. doi:10.1002/ajpa.1330210212.
- Ogden, J. A. 2000. *Skeletal Injury in the Child*. New York: Springer.
- Ortner, D. J. 2003. *Identification of Pathological Conditions in Human Skeletal Remains*. San Diego: Academic Press.
- Piessens, D. 2014. "De Sint-Romboutsparochie te Mechelen op het einde van de 18e eeuw: Een historisch-demografische studie." Bachelor thesis. Vrije Universiteit Brussel.
- Redfern, R. C. 2017. *Injury and Trauma in Bioarchaeology. Interpreting Violence in Past Lives*. Cambridge: Cambridge University Press.
- Robb, J., R. Bigazzi, L. Lazzarini, C. Scarsini, and F. Sonogo. 2001. "Social 'Status' and Biological 'Status': A Comparison of Grave Goods and Skeletal Indicators from Pontecagnano." *American Journal of Physical Anthropology* 115: 213–222.
- Roberts, C. 2000. "Trauma in a Biocultural Perspective: Past, Present and Future Work in Britain." In *Human Osteology in Archaeology and Forensic Science*, edited by M. Cox and S. Mays, 337–356. Cambridge: Cambridge University Press.
- Roberts, C., and M. Cox. 2003. *Health and Disease in Britain. From Prehistory to the Present day*. Stroud: Sutton Publishing.
- Salter, R. B., and W. R. Harris. 1963. "Injuries Involving the Epiphyseal Plate." *The Journal of Bone and Joint Surgery* 45 (3): 587–622.
- Scheuer, L., and S. Black. 2000. *Developmental Juvenile Osteology*. London: Academic Press.
- Sellier, P. 2011. "Tous les morts? Regroupement et sélection des inhumés: Les deux pôles du 'recrutement funéraire'." In *Le regroupement des morts: Genèse et diversité archéologique*, edited by D. Castex, P. Courtaud, H. Duday, F. Le Mort, and A-M. Tillier, 83–94. Bordeaux: Maison des Sciences de l'Homme d'Aquitaine.
- Shahar, S. 1990. *Childhood in the Middle Ages*. New York: Routledge.



- Sigal, P. A. 1997. "Les accidents de la petite enfance à la fin du Moyen Âge d'après les récits de miracles." In *La petite enfance dans l'Europe médiévale et moderne. Actes des XVes Journées Internationales d'Histoire de l'Abbaye de Flaran Septembre 1994*, edited by R. Fossier, 59–76. Toulouse: Presses Universitaires de Mirail.
- Sofaer, J. 2006. *The Body as Material Culture. A Theoretical Osteoarchaeology*. Cambridge: Cambridge University Press.
- Stuart-Macadam, P., B. Glencross, and M. Kricun. 1998. "Traumatic Bowing Deformities in Tubular Bones." *International Journal of Osteoarchaeology* 8 (4): 252–262. doi:10.1002/(SICI)1099-1212(199807/08)8:4<252::AID-OA425 > 3.0.CO;2-Z.
- Van de Vijver, K. 2018. "Past Life and Death in a Flemish Town. An Archaeo-Anthropological Study of Burials from the Medieval and Post-medieval St. Rombout's Cemetery in Mechelen, Belgium (10th–18th Centuries CE)." *Journal of Archaeological Science: Reports* 20: 524–555. doi:10.1016/j.jasrep.2018.05.007.
- Van de Vijver, K. 2019. "Unraveling the Motives Behind Multiple Burial in St. Rombout's Cemetery in Mechelen, Belgium, Tenth-Eighteenth Centuries A.D." *Bioarchaeology International* 2 (4): 255–282. doi:10.5744/bt.2018.1027.
- Verlinden, P., and M. E. Lewis. 2015. "Childhood Trauma: Methods for the Identification of Physeal Fractures in Nonadult Skeletal Remains." *American Journal of Physical Anthropology* 157: 411–420. doi:10.1002/ajpa.22732.
- Waldron, T. 2009. *Palaeopathology, Cambridge Manuals in Archaeology*. Cambridge: Cambridge University Press.